

## **Corneal Findings in Patients Treated with Belantamab Mafodotin**

### **– A Prospective Case Series Focusing on Corneal Nerves**

*Jakob Schweighofer<sup>1</sup>; Hermine Agis<sup>2</sup>; Maria Krauth<sup>2</sup>; Ruth Donner<sup>1</sup>; Marion Funk<sup>1</sup>; Jan Lammer<sup>1</sup>,  
Michal Klimek<sup>1</sup>, Gerald Schmidinger<sup>1</sup>; Julia Aschauer<sup>1</sup>*

#### *Affiliations:*

*1: Department of Ophthalmology and Optometry, Medical University of Vienna, Vienna, Austria.*

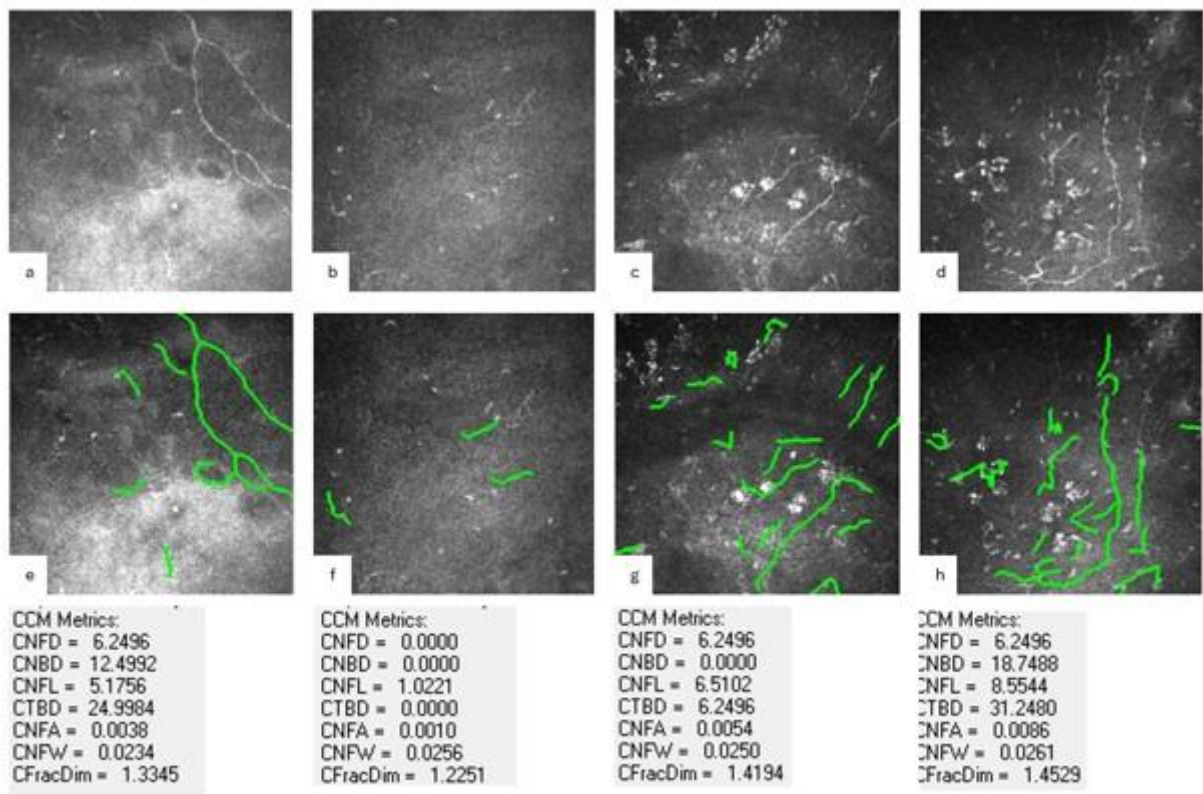
*2: Clinical Division of Hematology and Hemostaseology (H.A.), Department of Internal Medicine I, Medical University of Vienna, Vienna, Austria.*

#### Corresponding author:

Julia Aschauer,

Medical University of Vienna, Spitalgasse 23, 1090, Vienna, Austria

e-mail: [Julia.aschauer@meduniwien.ac.at](mailto:Julia.aschauer@meduniwien.ac.at)



Supplementary Figure 1